



PATIENT

Ellie Gray

SPECIES

Canine

BREED

Boston Terrier

SEX

Female Spayed

AGE

7 years

WEIGHT

17.2lbs

INTERPRETED BY

Maggie Machen Lamy,
DVM, DACVIM
(Cardiology)

IMAGING PERFORMED BY

Mariusz Chmielinski,
DVM

HOSPITAL NAME

Apex Veterinary
Services Ltd.

REFERRING VET

SAVE Emergency / ER
doctor

INVOICE

45891

DATE

11/21/25

PRESENTING CLINICAL SIGNS

History: Grade 4/6 heart murmur. Collapse episodes; becomes very weak/limp, which they were attributing to seizures. Acts like herself between these episodes and seems to snap out quick. Suspect 2nd degree AV block. Sedated with Gabapentin, Trazadone and Torb – limited exam due to aggression.

ELECTROCARDIOGRAPHIC FINDINGS *Note: Single lead ECGs are evaluated as a rhythm strip. Morphology/MEA cannot be definitively commented on.

A single lead ECG is available; 25mm/s, 10mm/mV. The rhythm diagnosis is complete/3rd degree AV block. The sinus/P wave rate is 150bpm. A ventricular escape rhythm is present with an average HR of 43bpm.

ECG diagnosis: Complete/3rd degree AV block with a slow ventricular escape rhythm.

ECHOCARDIOGRAM FINDINGS

2D, m-mode, color flow and doppler imaging is available. Mild diffuse thickening of mitral valve leaflets with no prolapse into the left atrial lumen. Mild central diastolic mitral regurgitation with no left atrial dilation. Normal LV diameter with adequate myocardial function. The tricuspid valve appears normal with trace tricuspid regurgitation. Normal right atrial and ventricular diameter and morphology indicating no overt evidence of pulmonary arterial hypertension. The pulmonic and aortic valves are normal in morphology and mobility. Mildly elevated pulmonic and aortic outflow velocities with laminar flow. No obvious aortic and mild pulmonic insufficiency. No pericardial or pleural effusion noted. No obvious cardiac masses.

CARDIAC CHART

CANINE CARDIAC PARAMETERS	MR VMAX (m/s)	TR VMAX (m/s)	LA/AO (Boon method)	LA/AO (Heart Base; Swe)	FS (%)	EF (%)	EPSS (cm)
NORMAL PARAMETER	4.5-5.5	<2.7	1.3	<1.6	28-40	40-100	<0.6
PATIENT	NA	NA	1.5	1.4	65	94	NM
CANINE CARDIAC PARAMETERS	HR (BPM)	AV VMAX (m/s)	PV MAX (m/s)	BODY WEIGHT (kg)	LA 2D short axis Base view (cm)	LVIDd Avg; 2D and m-mode short axis (cm)	LVIDs Avg; 2D and m-mode short axis (cm)
NORMAL PARAMETER	50-100	0.7-1.7	0.7-1.6	BELOW	BELOW	BELOW	BELOW
PATIENT	NM	2.8	2.0	7.8	2.3	3.3	1.2
*Normal chamber parameters expressed as a mean value (SD)				3	1.27 (5.3)	2.46 (2.46)	1.36 (5.5)
BODY WEIGHT DEPENDENT PARAMETERS				5	1.40 (4.5)	2.74 (5.2)	1.60 (4.7)
*Note: All measurements based upon multi-modal images and methods. An average value is reported.				10	1.50 (3.8)	3.27 (3.5)	2.06 (3.1)
				15	1.83 (2.0)	3.71 (2.4)	2.43 (2.1)
				20	2.02 (1.9)	4.14 (2.2)	2.80 (2.0)
				25	2.18 (2.4)	4.48 (2.9)	3.10 (2.5)
				30	2.33 (3.3)	4.83 (3.9)	3.39 (3.4)
				35	2.48 (4.3)	5.17 (5.0)	3.69 (4.5)
				40	2.62 (5.2)	5.48 (6.1)	3.96 (5.4)
				50	2.88 (7.1)	6.07 (8.3)	4.46 (7.4)

Adapted from June Boon, Veterinary Echocardiography, 1998
Rishniw M and Hollis NE, J Vet Intern Med 2000; 14:429-435
Hansson et al, Vet Rad and Ultrasound 2002
Bonagura et al. Echocardiography: principles of interpretation, Vet Clin North Am 15:1177, 1995



PATIENT

Ellie Gray

SPECIES

Canine

BREED

Boston Terrier

SEX

Female Spayed

AGE

7 years

WEIGHT

17.2lbs

INTERPRETED BY

Maggie Machen Lamy,
DVM, DACVIM
(Cardiology)

IMAGING PERFORMED BY

Mariusz Chmielinski,
DVM

HOSPITAL NAME

Apex Veterinary
Services Ltd.

REFERRING VET

SAVE Emergency / ER
doctor

INVOICE

45891

DATE

11/21/25

INTERPRETATION OF THE FINDINGS & FURTHER RECOMMENDATIONS

The rhythm diagnosis is 3rd degree AV block with a ventricular escape rate of 43bpm. Significant bradycardia and AV block is usually an acutely progressive disorder, with most dogs requiring transvenous pacemaker implantation to relieve clinical signs such as collapse or lethargy. The overall cardiac dimensions are normal with mild sub-clinical MR and TR; these are likely due to the arrhythmia (diastolic leaks being seen with AV block) and are hemodynamically insignificant. The murmur is due to increased flow velocity through both great vessels, which is secondary to bradycardia. No additional issues are identified at this time.

AV block is typically idiopathic in origin, with progressive deterioration of the electrical system resulting in persistent bradycardia, significant lethargy and collapse. An atropine challenge should be performed; however, response is expected to be minimal. Baseline full lab work should be performed, to rule out any electrolyte abnormalities that may be contributing.

Barring any treatable systemic issues, the recommended treatment in this case is referral for discussion of pacemaker implantation, particularly given that the patient is collapsing. If declined, heart rate stimulation can be attempted as discussed; however, this is of little benefit. Going forward, the arrhythmia will likely progress and if not corrected, the patient will succumb to either continued cardiac dilation over time resulting in CHF (which will be difficult to manage in the absence of a normal heart rate), or to worsening bradycardia/syncope/sudden death. The goal would be to stabilize the situation through heart rate management and use medical support to hopefully support the structural disease.

No obvious indication for cardiac supportive medications at this time given only mild atrial dilation. That being said, Pimobendan would be reasonable for long term cardiac support as blow. Going forward, unfortunately, the patient will always be at risk for recurrent CHF, syncope and/or sudden death in the future. **If QOL suffers and referral is declined, euthanasia or pacemaker implantation will become the only options, and this should be expressed to the owner.**

PLAN

Consider immediate referral to a tertiary facility for further evaluation of the bradyarrhythmia and discussion of surgical intervention. Full systemic screening as discussed.

If referral is declined/not possible, attempt oral management with Theophylline 10mg/kg PO q12h. If no improvement, the medication will likely be of little benefit.

If patient improves at home, consider Pimobendan 0.3mg/kg PO q12h.

If patient continues to do well at home (i.e., no collapse or lethargy), reassess echo/ECG in 3-4 months.



PATIENT

Ellie Gray

SPECIES

Canine

BREED

Boston Terrier

SEX

Female Spayed

AGE

7 years

WEIGHT

17.2lbs

INTERPRETED BY

Maggie Machen Lamy,
DVM, DACVIM
(Cardiology)

IMAGING PERFORMED BY

Mariusz Chmielinski,
DVM

HOSPITAL NAME

Apex Veterinary
Services Ltd.

REFERRING VET

SAVE Emergency / ER
doctor

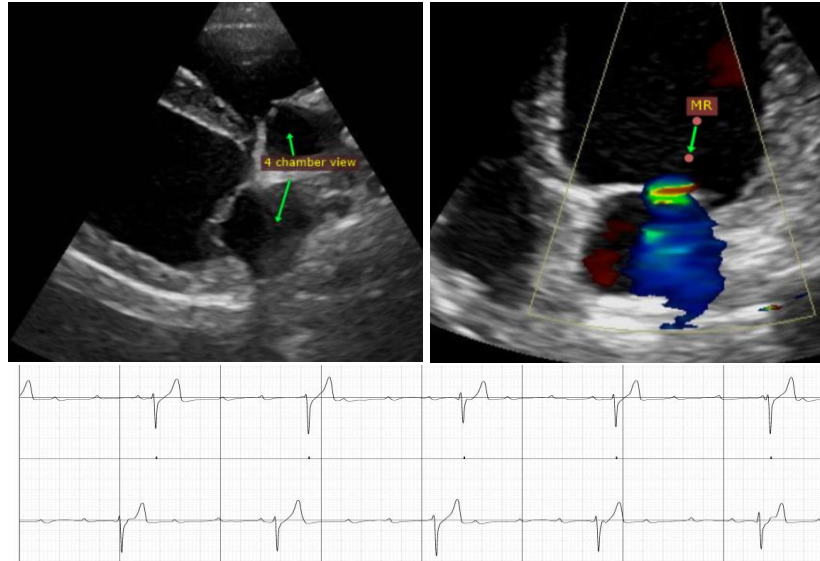
INVOICE

45891

DATE

11/21/25

IMAGES



The information and recommendations provided are based on the images presented by the referring veterinarian. No evaluation can be communicated regarding pathology that was not visible in the image/video clips provided.

Thank you for this referral. This report was generated using transcription software, and minor dictation errors may be present. If the clinical or image interpretation does not parallel your findings or if I can be of any further assistance, please contact me.

Maggie Machen Lamy, DVM
Diplomate of the American College of Veterinary Internal Medicine (Cardiology)
info@sonopath.com